XIAPEX®
collagenase clostridium histolyticum

Injection Training Brochure
Dupuytren's Contracture

The following training brochure is designed to ensure appropriate treatment of patients with Dupuytren's contracture with Xiapex

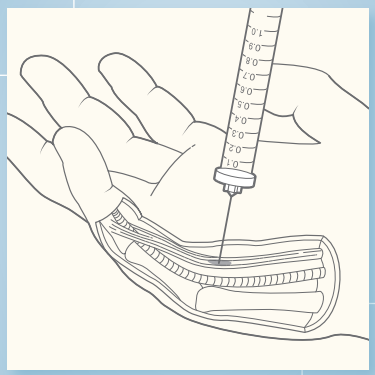

Date of preparation: Oct 2016 NP-1535

Contents

3 Summary

4 Dupuytren's Disease and hand anatomy

7 Xiapex Overview

8 Information to share with patients

9 Xiapex preparation for administration

10 Xiapex reconstitution protocol

11 Treating cords affecting MP joints

13 Treating cords affecting PIP joints

15 Xiapex injection aftercare and patient observation

16 Xiapex finger extension procedure and outpatient treatment

18 Xiapex additional information

20 Adverse reaction reporting

Date of preparation: Oct 2016 NP-1535

Summary

This training brochure covers the following points:

- An overview of Dupuytren's Disease and the anatomy of the hand
- Injection technique and dosing interval
- Dosage for both reconstitution and injection differences in the metocarpophalangeal (MP) and proximal interphalangeal (PIP) joints for Dupuytren's contracture
- Finger extension procedure for disrupting the cord
- Recognition and treatment of severe immune-mediated reaction, including anaphylaxis
- Information on bleeding risk in patients with coagulation disorders including those on concurrent anti-coagulation therapy
- Information on the potential risk of matrix metalloproteinases (MMP) cross reactivity including the development of musculoskeletal syndrome and exacerbation/initiation of autoimmune disorders
- Reminder of the need to report adverse events, including medication errors
- The need to inform the patient about the signs and symptoms associated with the treatment and when to seek attention from the health care provider
- The summary of product characteristics and the patient information leaflet

Dupuytren's disease and hand anatomy

Dupuytren's disease is a slowly progressive connective tissue disorder that affects the palmar fascia of the hand. It can lead to flexion contractures at the digital joints, resulting in significant functional impairment and disability.

During the initial proliferative stage of the disease, fibroblasts transform into myofibroblasts, with accompanying collagen deposition and nodule formation. The subsequent involutional stage involves alignment of myofibroblasts along the lines of tension. Nodules thicken, cords form and contractures start to develop. In the final residual phase the myofibroblasts disappear, leaving thick bands of collagen and progressive contractures.

The joints most commonly affected in Dupuytren's disease are the metacarpophalangeal joint (MP) and the proximal interphalangeal joint (PIP), with the ring and little fingers most frequently presenting with a contracture. Involvement of the thumb and index finger is not uncommon, but usually milder. The disease is often bilateral and can affect multiple fingers.

Overview of hand anatomy[1–4]

The palmar fascial complex is the centre of activity in Dupuytren's disease. It comprises five anatomical components: the radial (thenar) aponeurosis (RA), the ulnar (hypothenar) aponeurosis (UA), the central (palmar) aponeurosis (PA), the palmo-digital fascia and the digital fascia (Figure 1).

The palmar aponeurosis consists of three types of fibres: longitudinal fibres, transverse fibres and vertical, or superficial, fibres.

The vertical fibres run obliquely toward the skin and at the metacarpal heads give rise to the distal palmar crease. The tight attachment of these fibres to the skin produces the dimpling of the palmar skin that is often seen in Dupuytren's. The longitudinal fibres form structures that are called bands.

The palmar fascia

The longitudinal fibres fan out and separate into four pretendinous bands at the level of the head of the four metacarpal bones which lead to the 2nd, 3rd, 4th and 5th digits. Another, shorter pretendinous band extends to the thumb, but it is weak and not always present.

At the distal edge of the metacarpals (in the palmo-digital fascia), the pretendinous longitudinal fibres terminate and separate into 3 layers (Figure 2). The deep layer passes dorsally and almost vertically. The superficial layer attaches to the skin at the palmar digital crease (the crease at the base of the finger on the volar side of the hand).

Figure 1. The palmar fascial complex

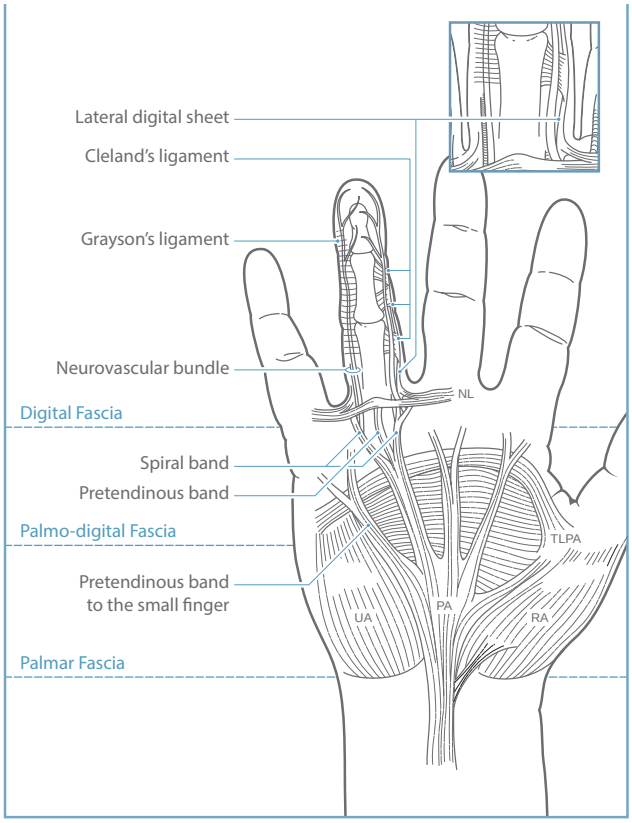

The digital fascia

The central layer of the pretendinous longitudinal fibres bifurcates into two bands which extend onto each side of the flexor tendons. These travel distally and dorsally to form the web space coalescence, passing deep to the natatory ligament (Figure 1). The fibres rotate 90 degrees and emerge distally to the natatory ligament (NL), then continue as the lateral digital sheets.

Figure 2. Longitudinal fibres in the fascia

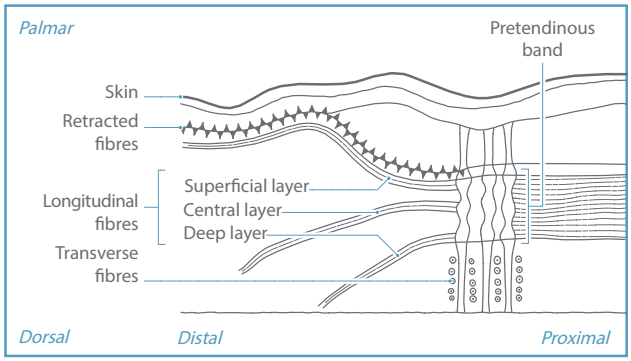

These sheets are lateral to the neurovascular bundle. Coronal fibres project from the lateral digital sheets on each side of the neurovascular bundle at the volar side (Grayson's ligament) and dorsal side (Cleland's ligament). It is important to note that the neurovascular bundle lies deep to the palmar fascia and becomes more superficial when it approaches the fingers.

Digital flexors

The primary flexors of the digit are the flexor digitorum profundus (FDP) and the flexor digitorum superficialis (FDS) tendons (Figure 3).

Figure 3. The flexor and extensor apparatus

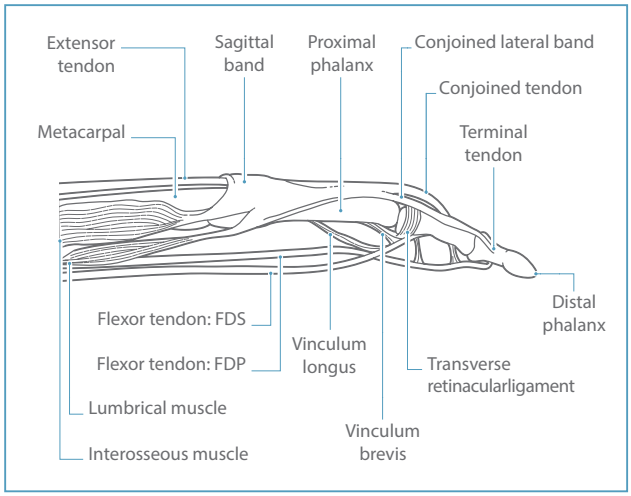

At the MP joint, the FDS tendon enters the digital flexor sheath with the FDP tendon. Once within the sheath, the FDS tendon starts to flatten. At the proximal third of the proximal phalanx it splits and passes around the FDP tendon, to reunite deep to the FDP tendon.

The FDS tendon continues dorsally to its insertion point at the volar base of the middle phalanx. At the level of the PIP joint, the FDP tendon is palmar to the FDS tendon and continues distally to the level of the distal interphalangeal (DIP) joint. There it inserts broadly onto the base of the proximal volar third of the distal phalanx.

The flexor sheath comprises of pulleys which keep the flexor tendons close to the centre of rotation, thus helping to control flexion in the digits.

Pathoanatomy of Dupuytren's disease[1–3]

In Dupuytren's disease normal fascia bands develop into cords, which shorten and lead to contractures of the MP, PIP and, sometimes, DIP joints. As well as causing contractures, some cords can displace neurovascular structures, putting them at risk of damage during corrective surgery or percutaneous needle fasciotomy.

Skin pits form in the palm between the distal palmar crease and the palmar digital crease, owing to contracture of the superficial layer of the pretendinous band that inserts into the skin.

Types of cords

Several main types of cords have been identified, although substantial variability has been observed: the pretendinous cord, the natatory cord, the spiral cord, the central cord and the lateral cord (Figures 4 and 5).

The pretendinous cord is the cord that is most commonly seen in Dupuytren's disease and derives from the pretendinous band. It typically causes MP contractures.

The natatory cord develops from the natatory ligament and can produce contractures of the 2nd, 3rd and 4th web spaces, limiting abduction.

Figure 4. Dupuytren's cords

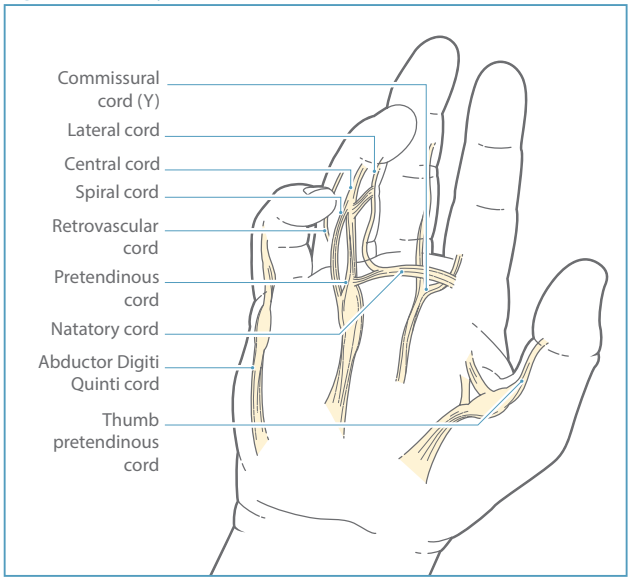

The spiral cord can develop from the pretendinous band, the lateral digital sheet and Grayson's ligament. It leads to contractures of the MP and PIP joints, usually in the 5th finger, but also in the other fingers. In the palm, the spiral cord is superficial to the neurovascular bundle. In the digit, it spirals around the bundle in the early stages of Dupuytren's disease but, as the fascia thickens and contracts, it becomes straighter. This leads to the displacement of the neurovascular bundle, (which now coils around the cord), to the midline of a finger. The greater the contracture of the spiral cord, the more the neurovascular structures are displaced superficially and towards the midline, putting them at risk of injury during surgery or percutaneous needle fasciotomy.

Although it occurs less frequently, another important consideration is the so called "spiral nerve". In some cases spiral cords, particularly those which originate deep in the palm, may cross under the neurovascular bundle or the digital nerve only (due to its more proximal division than the accompanying artery) displacing it proximally and towards the midline. This can sometimes be indicated by a circular area of pulpy, soft 'redundant skin' in the palm on either side of the cord at the level of MP joint. Similar phenomenon has been observed for axial digitopalmar cords (e.g. central cords). This is also important to identify prior to any corrective procedure.

The central cord usually has no fascial precursor and is usually an extension of the pretendinous cord to the fingers. It occurs in the midline and attaches into the flexor tendon sheath near the PIP joint. It does not usually displace the neurovascular bundle.

Lateral cords originate from the lateral digital sheet and attach to the skin or the flexor tendon sheath near Grayson's ligament. These result in PIP contractures and sometimes contractures of the DIP joints. Owing to their volume, lateral cords can displace the neurovascular bundle to the midline.

Other types of cord may also occur.

The abductor digiti quinti cord, or isolated digital cord, forms in the 5th finger from the abductor digiti quinti muscle. It runs superficially to the neurovascular bundle, but may occasionally trap and displace it.

Retrovascular cords may sometimes present, but are poorly defined and thought to originate from the retrovascular band, located deep to the neurovascular bundle. They do not cause PIP contractures.

Commissural cords may form in the thumbs from the distal commissural ligament (the radial extension of the natatory ligament) and the proximal commissural ligaments (the radial extension of the transverse ligament of the palmar aponeurosis). Both of these cords cause contracture of the first web space. A pretendinous cord in the thumb is uncommon, but if present can cause flexion deformity of the thumb MP joint.

The differences between the normal and abnormal finger anatomy are depicted below (Figure 5). These diagrams demonstrate the pathological changes that occur in the development of Dupuytren's disease in the finger.

Figure 5. Anatomy of the finger

Normal

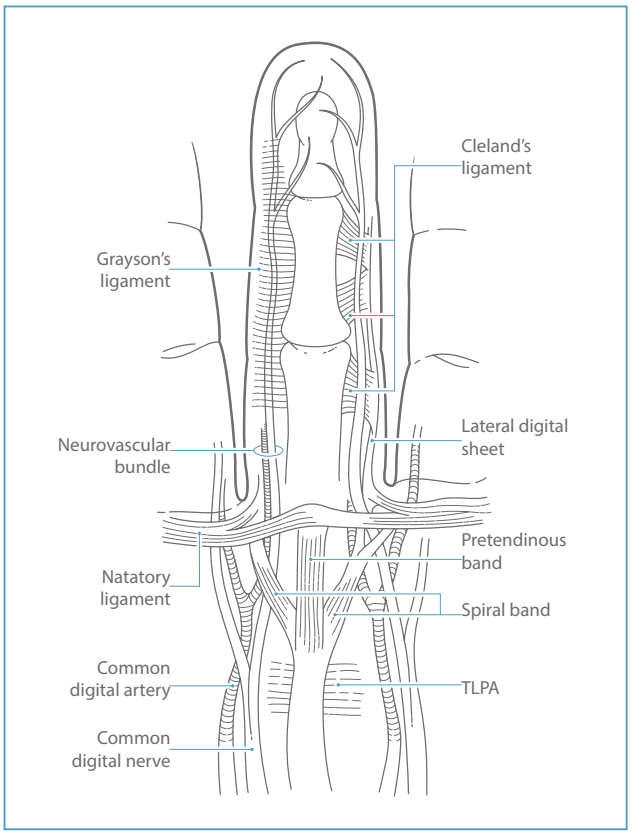

Abnormal

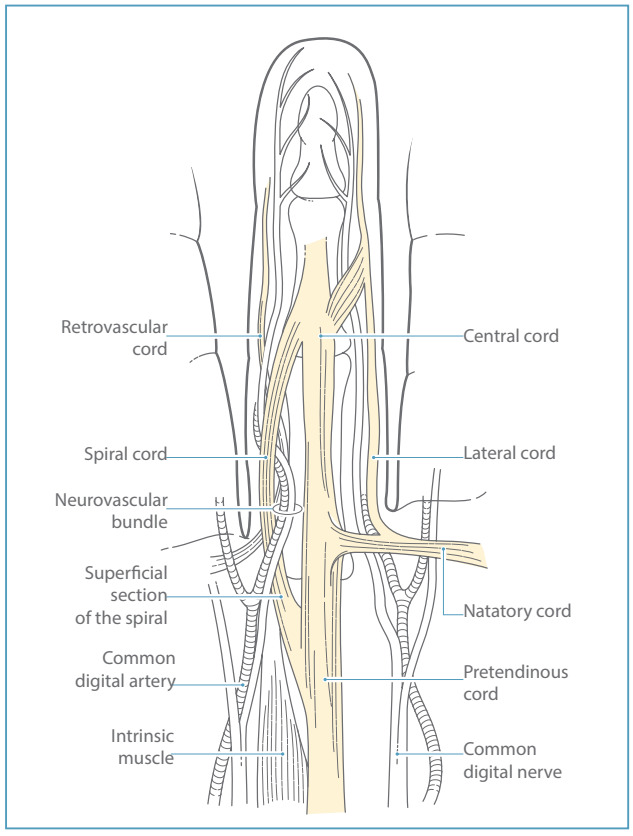

Xiapex Overview

• Xiapex (collagenase clostridium histolyticum) is indicated in treatment of patients with Dupuytren's contracture presenting with a palpable cord.

• Xiapex is also indicated for the treatment of adult men with Peyronie's Disease with a palpable plaque and curvature deformity of at least 30 degrees at the start of therapy.[6] Please refer to the Xiapex Peyronie's Disease Injection Training Brochure for more information.

• Xiapex is composed of two distinct collagenases (AUX-I and AUX-II) that are isolated and purified from the bacterium Clostridium histolyticum. The pharmacologic activity involves selective lysis of collagen at the site of injection. The two collagenases work in a complementary fashion to cleave the collagen chains and disrupt the pathologic collagen cords that cause Dupuytren's contractures. (Figure 6).

• Dupuytren's cords are composed primarily of types I and III collagen, which are substrates for both the collagenases AUX-I and AUX-II. Other soft tissues of the hand, including ligaments and tendons, are also susceptible to the action of these collagenases, making it necessary for the treating physician to understand the mechanism of action and the appropriate administration procedure of Xiapex. Importantly, the supporting structures of nerves, arteries and veins are composed primarily of type IV collagen, which is resistant to the action of Xiapex.

Figure 6. Xiapex mechanism of action

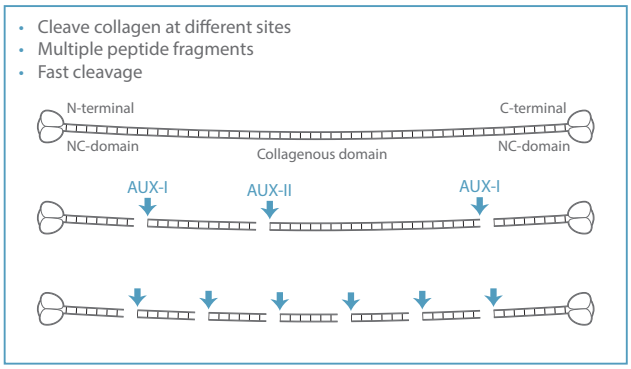

Xiapex must be administered by a physician appropriately trained in the correct administration of the product and experienced in the diagnosis and management of Dupuytren's disease

Information to share with patients

It is important that, prior to Xiapex administration, the physician ensures that patients clearly understand the following information.

Procedures to be performed and the desired treatment outcome

• Treatment with Xiapex consists of an injection, followed by a finger extension procedure to disrupt the Dupuytren's cord 24-72 hours later. In some cases satisfactory outcome can be achieved after just one injection. However, in other instances more than one treatment may be required per cord. Up to a maximum of 3 injections can be performed to the same cord at 4 week intervals, if the cord has not ruptured.

• Local anaesthesia may be an option during the finger extension procedure at the physician's discretion and in discussion with the patient.

• It is important to mention that, even with successful disruption of a treated cord, there can be recurrence of the contracture.

Use in patients with coagulation disorders

• Xiapex must be used with caution in patients with coagulation disorders or those taking anticoagulants.

• Increased risk of bleeding can occur in patients who receive Xiapex with coagulation disorders, including those on concurrent anti-coagulation therapy. Patients with blood clotting disorders need to be advised on the bleeding risk prior to treatment. Advice should also be given to patients on what action they should take in the event of a bleed.

• Use of Xiapex in patients who have received anticoagulants (with the exception of up to 150 mg acetylsalicylic acid daily) within 7 days prior to receiving an injection of Xiapex is not recommended.

Interaction with other medicinal products and other forms of interaction

• Caution should be used when administering Xiapex in patients receiving concomitant fluoroquinolone antibiotics (ciprofloxacin, norfloxacin, ofloxacin, gatifloxacin, gemifloxacin, levofloxacin and moxifloxacin) due to a potentially higher risk for tendon injury associated with concomitant fluoroquinolone use.

• Treatment with Xiapex is not recommended in patients who have received tetracycline antibiotics within 14 days prior to receiving an injection.

Precautions during pregnancy

• Female patients should be made aware that the use of Xiapex is not recommended in pregnancy and treatment should be postponed until after pregnancy.

Contraindications

• Xiapex is contraindicated in patients with previous hypersensitivity to collagenase or any of the product excipients.

Allergic reactions

• Following Xiapex injection, severe allergic reaction could occur, and patients should be observed for 30 minutes before leaving the clinic in order to monitor for any signs or symptoms of a serious allergic reaction, e.g. wide spread redness or rash, swelling, tightness in the throat or difficulty breathing. Patients should be instructed to consult a doctor immediately if they experience any of these signs or symptoms. Emergency medication for treatment of potential allergic reactions should be available.

• An anaphylactic reaction was reported in a post-marketing clinical study in a patient who had previous exposure to Xiapex for the treatment of Dupuytren's contracture, demonstrating that severe reactions including anaphylaxis can occur following Xiapex injections. Some patients with Dupuytren's contracture developed IgE-anti-drug antibodies in greater proportions and higher titers with successive Xiapex injections.

• In the double blind portion of the three phase 3 placebo-controlled clinical studies in Dupuytren's contracture, 17% of Xiapex-treated patients had mild reactions (i.e. pruritus) after up to 3 injections. The incidence of Xiapex-associated pruritus increased after more Xiapex injections in patients with Dupuytren's contracture.

Potential risks

• There is also a theoretical risk of reactions related to cross-reactivity with endogenous human matrix metalloproteinases (MMPs) (including the development of a musculo-skeletal syndrome and the development or exacerbation of autoimmune disorders) although clinical evidence of this has not been observed.

• For more information please refer to Xiapex Summary of Product Characteristics and the Patient Information Leaflet. The Patient Information Leaflet included in the package, must be given to the patient at each visit to take home. The Patient Information Leaflet contains the important information that you should discuss with each patient.

Xiapex preparation for administration

Xiapex dosing

The dose of Xiapex to be administered is 0.58 mg per injection into a palpable Dupuytren's cord.

Up to two cords or two affected joints in the same hand can be treated according to the injection procedure during a treatment visit. Two palpable cords affecting two joints or one palpable cord affecting two joints in the same finger may be injected at two locations. When administering two injections in the same hand during a treatment visit, begin with the affected finger in the most ulnar aspect of the hand and continue toward the radial aspect (eg, fifth finger to index finger). Within each finger, begin with the affected joint in the most proximal aspect of the finger and continue toward the distal aspect (eg, MP to PIP).

Each injection contains a 0.58 mg dose. If the disease has resulted in multiple contractures, additional cords may be treated at other treatment visits approximately 4 weeks apart.

Xiapex must be carefully reconstituted prior to use, using aseptic technique. Before reconstituting, check the package expiry to ensure it is within date. Confirm the joint to be treated (i.e. MP or PIP) as the volume of solvent required for reconstitution is determined by the type of joint (PIP joint requires a smaller volume for injection).

Each vial of Xiapex and sterile solvent for reconstitution should only be used for a single injection. If cords of two affected joints on the same hand are to be treated during a treatment visit, separate vials and syringes should be used for each reconstitution and injection.

Reconstitution of Xiapex

Xiapex is supplied in single-use glass vials containing 0.9 mg of sterile, lyophilised powder for reconstitution (Figure 7). Each vial of Xiapex should be reconstituted with the sterile solvent that is provided in the packet. This medicinal product contains less than 1 mmol sodium (23 mg) per dose, i.e. essentially 'sodium-free'.

The package containing Xiapex and the solvents should be kept refrigerated between 2°C and 8°C. Before reconstitution, the vials of Xiapex and solvent should be removed from the refrigerator and allowed to stand at room temperature (20 to 25°C), for at least 15 minutes, but no longer than 60 minutes.

Once the vials have been allowed to stand at room temperature, please follow the reconstitution protocol (Figure 8).

The reconstituted solution of Xiapex must be clear. Inspect the solution for particulate matter and discolouration prior to injection. If the solution is cloudy or discoloured, DO NOT inject Xiapex.

Reconstituted Xiapex can be kept at room temperature (20 to 25°C) for up to one hour, or refrigerated at 2°C to 8°C for up to four hours, prior to administration. If refrigerated, the solution must be allowed to return to room temperature for approximately 15 minutes before use.

Figure 7. Solvent and Xiapex vials



Before Xiapex is reconstituted, the person responsible for preparing the solution should ensure that the following are easily accessible in the treatment room:

1. Two hubless syringes with 0.01ml graduations and a permanently fixed half-inch, 26 or 27 gauge needle – one is for reconstitution of Xiapex and one is for the injection of Xiapex
2. Emergency medication for treatment of potential allergic reactions (an adrenaline injection kit and antihistamine medication for treatment of potential allergic reactions)
3. Dressing for the patient's finger post-injection
4. A copy of this training brochure which contains instructions for the preparation, injection and finger extension procedure

Xiapex reconstitution protocol

Figure 8. Xiapex reconstitution protocol

All steps for reconstitution of Xiapex should be carried out using aseptic technique, with sterile alcohol, and in line with current, local, standard of care. Before reconstituting Xiapex, check that the package is within date.

Step 1: Volume of sterile solvent required for reconstitution



Step 2: Injection volume to deliver 0.58mg of Xiapex

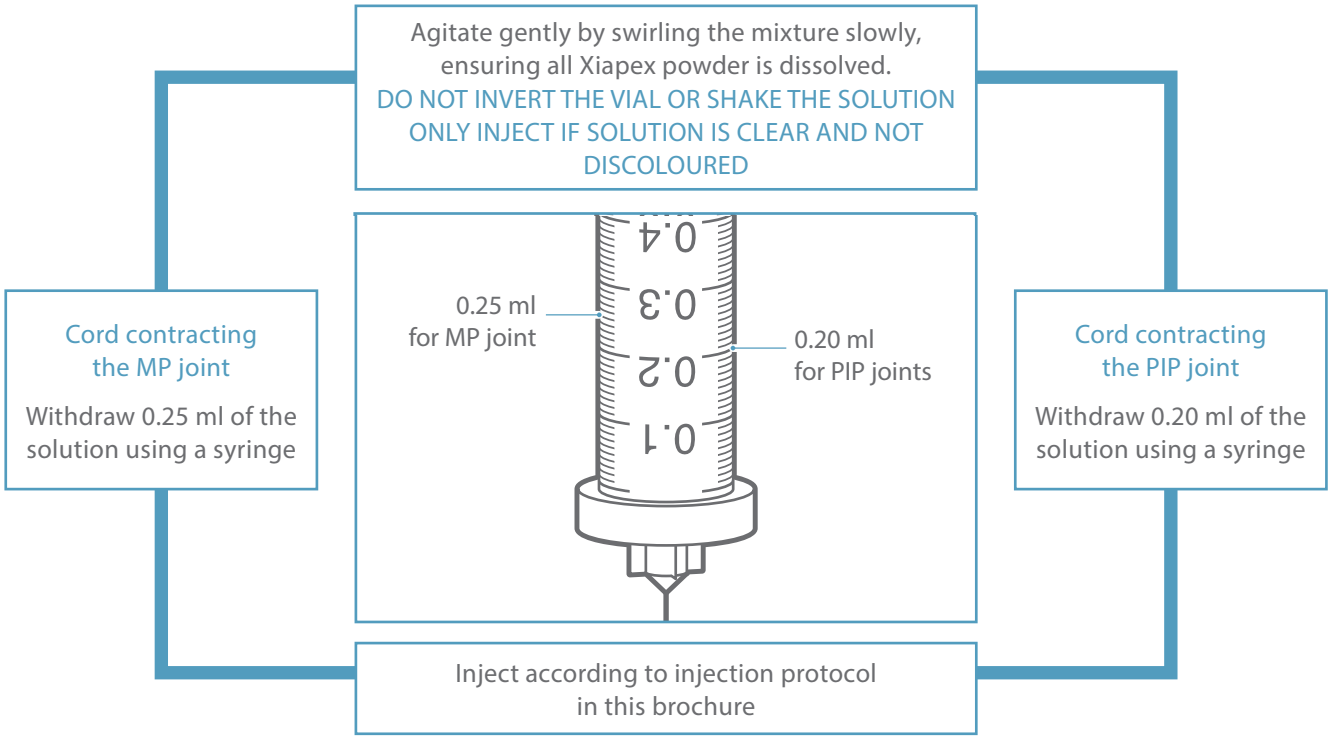

Additional information regarding the reconstitution procedure can be found in Section 6.6 of the Xiapex SmPC.

Treating cords affecting MP joints

• Please note that reconstitution volumes and injection volumes differ depending on which joint the cord to be treated is contracting.

• For cords contracting MP joints each dose should be reconstituted using 0.39 ml of solvent. The injection volume for cords contracting MP joints is 0.25 ml.

Table 1. Reconstitution volume for MP joint

Reconstitution of Xiapex single-use vial		
Joint to be treated	Sterile solvent required for reconstitution	Injection volume to deliver 0.58 mg of Xiapex
MP joint	0.39 ml	0.25 ml

Xiapex injection procedure

STEP 1
Selecting and preparing the injection site

• The optimal injection site is the point where the cord is furthest away from the underlying flexor tendon. Usually this is at the point of maximum 'bowstring' of the cord. The injection site must be at a point where the cord is not intimately adherent to the skin (Figure 9) to facilitate proper administration and decrease the risk of skin tearing during the finger extension procedure.

• Reconfirm the cord to be treated and ensure that the area is appropriately marked. The choice of injection site should take into account the probable position of other non-targeted structures within the hand, to minimise the exposure risk of tendons and ligaments to Xiapex. Recommended injection sites for cords contracting MP joints are shown in Figure 10.

• Note that in cases where both the MP and PIP joint are affected in the same digit, the cord affecting the MP joint should be treated initially, as successful disruption of the MP cord can decrease PIP contracture in the treated digit.

• Just prior to administration of Xiapex, the skin at the injection site should be prepared with a suitable antiseptic and allowed to dry.

• Administration of a local anaesthetic agent prior to injection of Xiapex is NOT recommended as it may interfere with the ability to detect paresthesia in cases where the needle has been inserted into a nerve.

Figure 9. Injection site selection – skin adherence to the cord in an MP joint contracture

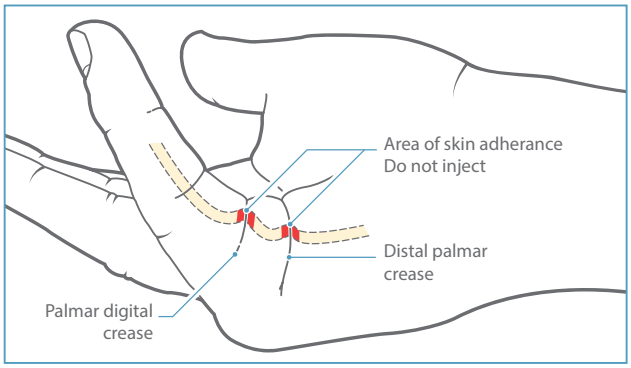

Figure 10. Injection site selection – MP joint contractures

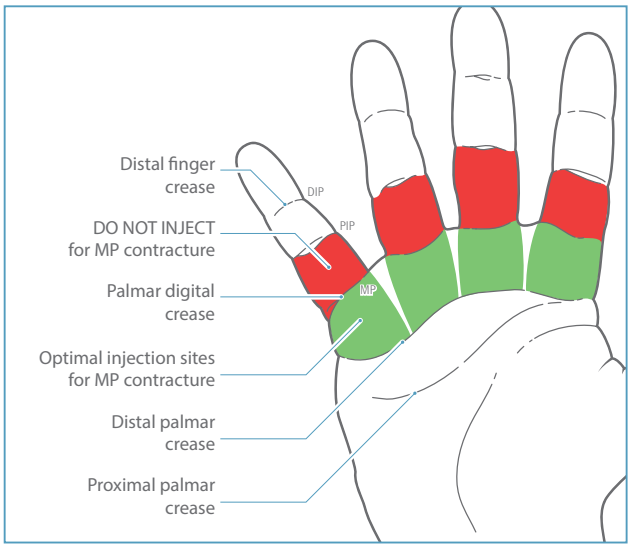

STEP 2
Inserting the needle

• Withdraw 0.25 ml of reconstituted Xiapex using a second hubless syringe.

• With your non-dominant hand, secure the patient's hand to be treated while simultaneously applying tension to the cord. With your dominant hand, insert the tip of the needle into the selected cord, taking care to keep the needle within the cord (Figure 11). Appropriate placement can be identified by the cord's increased resistance and gritty consistency. Avoid passing the needle tip through the cord, to minimise the possibility of injecting Xiapex into neighbouring tissues. The needle insertion should be no deeper than 2-3 mm. It may not be possible to feel a change in consistency as you pass through the cord, so the depth of the needle may be a helpful guide.

• If the insertion of the needle causes paresthesia or the needle is suspected to be in the tendon, withdraw the needle and reposition it into the cord. If placement of the needle is in question, ask the patient to slowly and carefully flex and extend the treated finger a few degrees at the DIP and PIP joints. If this causes movement of the needle then it is likely to be in the tendon and should be withdrawn and repositioned.

STEP 3
Xiapex administration

• After confirming that the needle is within the cord, depress the plunger of the syringe, taking care not to push the tip of the needle through the cord. One-third of the total dose should be injected into the first injection site. If the needle is in the proper location, there will be some resistance noted during the injection procedure.

• Withdraw the needle tip from the cord, keeping the needle tip under the skin, and reposition it to a slightly more distal location (approximately 2-3 mm) and, after ensuring the tip of the needle is within the cord, inject another one-third of the dose (Figure 12).

• Again, withdraw the needle tip from the cord, keeping the needle in the hand, and reposition it a third time proximal to the initial injection (approximately 2-3 mm); after ensuring the tip of the needle is within the cord, inject the final one-third of the dose (Figure 12).

• In cases where the subject has a Y-shaped commissural cord, created by combination of a central and a natatory cord, the injection should be made at the bifurcation of the cord (Figure 13).

Figure 11. Location of the injection

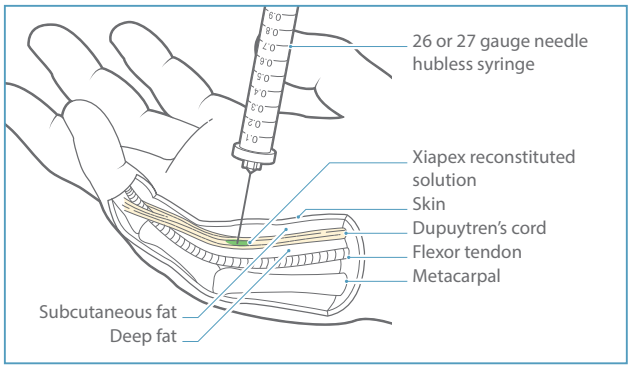

Figure 12. Injection target sites

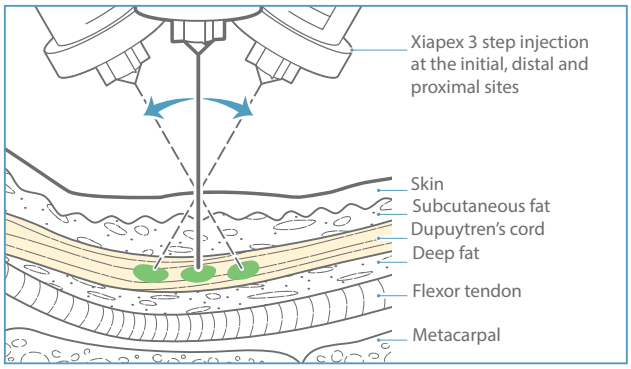

Figure 13. Image detailing the injection site for Xiapex into a Y-shaped cord

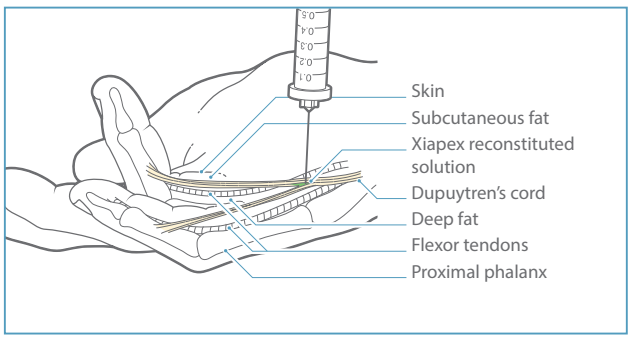

Discard the unused portion of the Xiapex reconstituted solution after injection and do not store, pool, or re-use.

Treating cords affecting PIP joints

• Please note that reconstitution volumes and injection volumes differ depending on which joint the cord to be treated is contracting.

• For cords contracting PIP joints each dose should be reconstituted using 0.31 ml of sterile solvent. The injection volume for cords contracting PIP joints is 0.20 ml.

Table 2. Reconstitution volume for PIP joint

Reconstitution of Xiapex single-use vial		
Joint to be treated	Sterile solvent required for reconstitution	Injection volume to deliver 0.58 mg of Xiapex
PIP joint	0.31 ml	0.20 ml

Xiapex injection procedure

Care and attention should be taken when injecting Xiapex into cords contracting the PIP joints as clinical studies indicate an increased risk of tendon rupture and ligament injury associated with treatment of PIP contractures with Xiapex. This is particularly important for cords situated at the PIP joint of the fifth finger.

STEP 1
Selecting and preparing the injection site

• The optimal injection site is the point where the cord is furthest away from the underlying flexor tendon. Usually this is at the point of maximum 'bowstring' of the cord. The injection site must be at a point where the cord is not intimately adherent to the skin (Figure 14) to facilitate proper administration and decrease the risk of skin tearing during the finger extension procedure.

• Reconfirm the cord to be treated and ensure that the area is appropriately marked. The choice of injection site should take into account the probable position of other non-targeted structures within the hand, to minimise the exposure risk of tendons and ligaments to Xiapex. Recommended injection sites for cords contracting PIP joints are shown in Figure 15.

• Note that in cases where both the MP and PIP joint are affected in the same digit, the cord affecting the MP joint should be treated initially, as successful disruption of the MP cord can decrease PIP contracture in the treated digit.

• Just prior to administration of Xiapex the skin at the injection site should be prepared with a suitable antiseptic and allowed to dry.

• Administration of a local anaesthetic agent prior to injection of Xiapex is NOT recommended as it may interfere with the ability to detect paresthesia in cases where the needle has been injected into a nerve.

• When treating a cord at the PIP joint, care should be taken to inject as close as possible to the palmar digital crease – no more than 4 mm distal to this crease (Figure 15). Therefore the point of maximum 'bowstring' of the cord within this area should be selected. This is particularly important for cords situated at the PIP joint of the fifth finger to reduce the risk of tendon or ligament injury.

Figure 14. Injection site selection – skin adherence to the cord in a PIP joint contracture

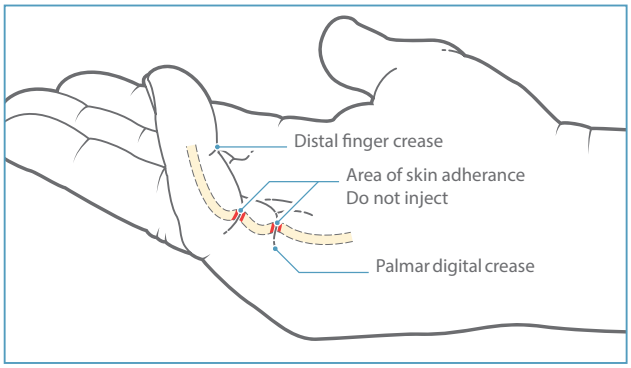

Figure 15. Injection site selection – PIP joint contractures

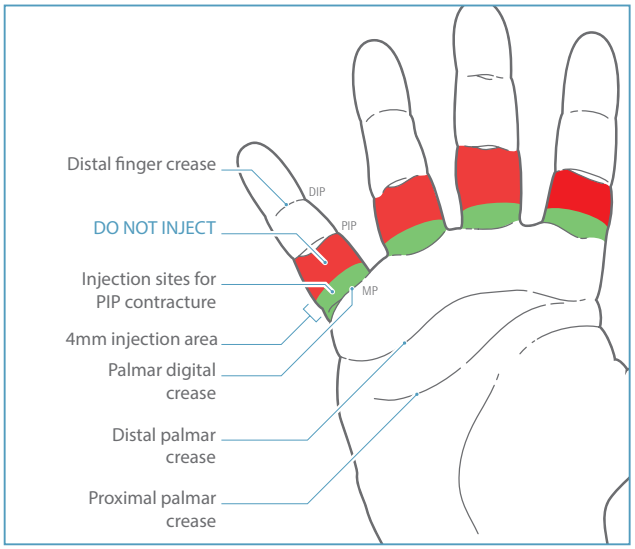

STEP 2
Inserting the needle

• Withdraw 0.20 ml of reconstituted Xiapex using the second hubless syringe.

• With your non-dominant hand, secure the patient's hand to be treated while simultaneously applying tension to the cord. With your dominant hand, insert the tip of the needle into the selected cord, taking care to keep the needle within the cord (Figure 16). Appropriate placement can be identified by the cord's increased resistance and gritty consistency. Avoid passing the needle tip through the cord, to minimise the possibility of injecting Xiapex into neighbouring tissues. The needle insertion should be no deeper than 2-3 mm. It may not be possible to feel a change in consistency as you pass through the cord, so the depth of the needle may be a helpful guide.

• If the insertion of the needle causes paresthesia or the needle is suspected to be in the tendon, withdraw the needle and reposition it into the cord. If placement of the needle is in question, ask the patient to slowly and carefully flex and extend the treated finger a few degrees at the DIP and PIP joints. If this causes movement of the needle then it is likely to be in the tendon and should be withdrawn and repositioned.

Figure 16. Location of the injection

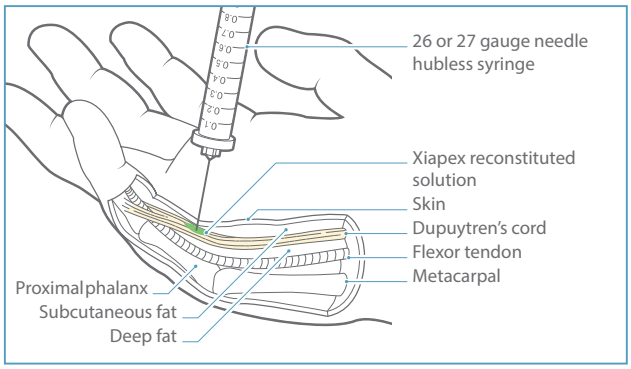

STEP 3
Xiapex administration

• After confirming that the needle is within the cord, depress the plunger of the syringe, taking care not to push the tip of the needle through the cord. One-third of the total dose should be injected into the first injection site. If the needle is in the proper location, there will be some resistance noted during the injection procedure.

• Withdraw the needle tip from the cord, keeping the needle tip under the skin, and reposition it to a slightly more distal location (approximately 2-3 mm) and, after ensuring the tip of the needle is within the cord, inject another one-third of the dose (Figure 17).

• Again, withdraw the needle tip from the cord, keeping the needle in the hand, and reposition it a third time proximal to the initial injection (approximately 2-3 mm); after ensuring the tip of the needle is within the cord, inject the final one-third of the dose (Figure 17).

Figure 17. Injection target sites

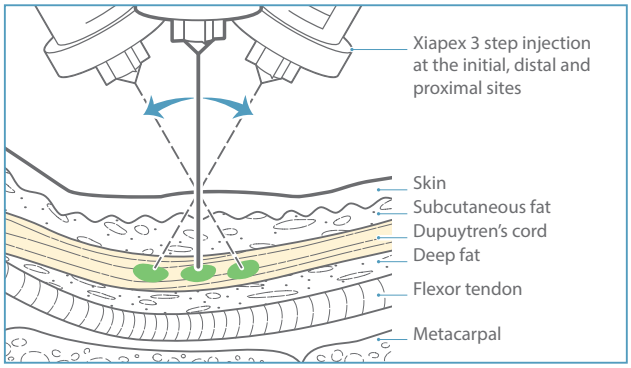

Discard the unused portion of the Xiapex reconstituted solution after injection and do not store, pool, or re-use.

Xiapex injection aftercare and patient observation

• Upon completion of the injection procedure, place a bulky dressing over the treated hand and instruct the patient to limit motion and refrain from use of the injected hand. They should be advised not to flex or extend the fingers of the injected hand, to reduce extravasation of Xiapex out of the cord.

• They should also be informed not attempt to disrupt the injected cord by self-manipulation and should elevate the injected hand as much as possible until the day after the finger extension procedure.

• After injection, the patient should be observed for 30 minutes for potential adverse reactions.

• After the observation period (30 minutes), the patient may leave the clinic providing he/she is stable and has exhibited no sign of systemic hypersensitivity or other systemic adverse reactions.

• The patient should be instructed to return approximately 24-72 hours after injection for the passive finger extension procedure.

Xiapex finger extension procedure and outpatient treatment

24-72 hours post injection

Since the injection some patients may have experienced a spontaneous rupture of the cord before their follow-up visit. If this has not occurred, a finger extension procedure will need to be performed in order to help facilitate rupture of the cord.

Local anaesthesia may be used at the physician's discretion during the finger extension procedure. The force exerted during extension of the finger should be uniform and persistent to the extent of the patient's pain threshold. Direct pressure to the site of the injection should be avoided as it will still be tender (Figures 18 and 19).

Finger extension should be performed for approximately 10-20 seconds. During the finger extension procedure, patients with skin adherent to the treated cord may experience skin tearing as the cord ruptures. If skin tearing occurs, standard wound care should be administered.

If manipulating a PIP joint the MP joint should be held in flexed position to isolate the forces of the extension procedure on the cord affecting the PIP joint.

If cords of two affected joints in one finger were treated, perform the finger extension procedure on the cord affecting the MP joint before performing the procedure on the cord affecting the PIP joint.

If the first finger extension procedure does not successfully rupture the cord, a second and third attempt can be made at 5-10 minute intervals as necessary.

No more than three finger extension procedures per cord should be attempted during one follow-up visit.

If the cord has not ruptured after three attempts, a subsequent clinic visit should be scheduled approximately four weeks later. If the cord causing the contracture remains intact, the patient can receive another treatment cycle of Xiapex, up to a maximum of three cycles (Figure 20).

Figure 18. Finger extension 1

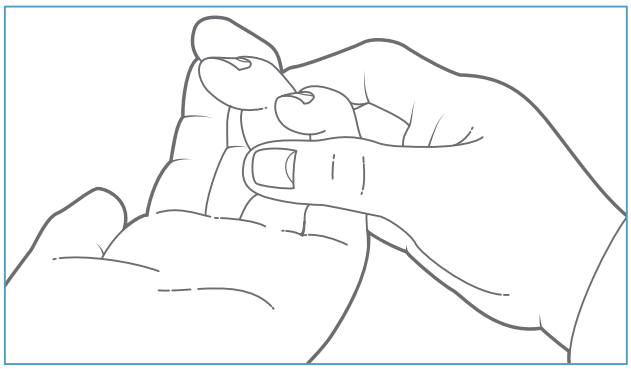

Figure 19. Finger extension 2

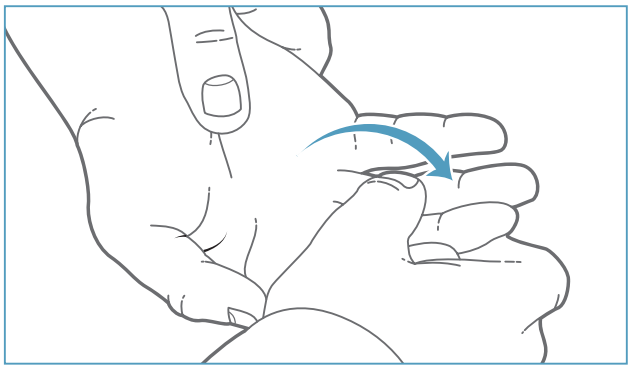

Figure 20. Repeated cycles of treatment

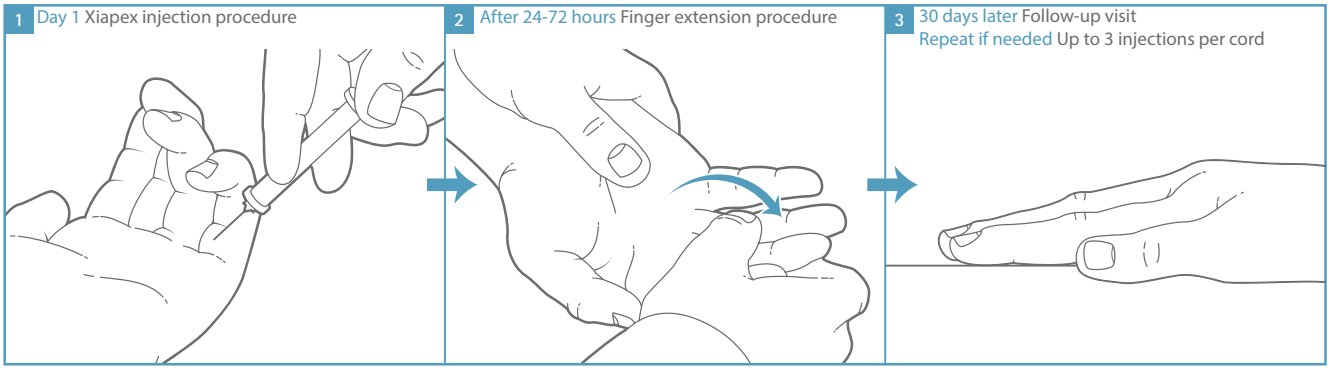

Post Day 1 follow up

Splinting is recommended following the finger extension procedure since, in the clinical development programme, patients were fitted for a splint to be worn at bedtime for up to four months.

Patients should also be instructed to carry out finger extension and flexion exercises at home. They should be encouraged to return to their normal daily activities, but not to undertake strenuous activities until advised.

Standard analgesia, wound care and management of bruising/swelling should apply to all patients, in keeping with the local standard of care.

Xiapex additional information

Injection precaution

Care should be taken to ensure that Xiapex is injected into the pathological cord causing the contracture and not into the surrounding tissues. An injection into any structures containing collagen can result in damage that can be permanent in some cases, such as tendon rupture and ligament injury. If tendon or ligament injury is suspected, the patient should be fitted with a splint and follow-up with an appropriate surgical specialist should be arranged.

Follow the injection procedure carefully to reduce the risk of tendon rupture or ligament injury.

Care should be taken when injecting Xiapex into cords contracting the PIP joints as clinical studies indicate an increased risk of tendon rupture and ligament injury associated with treatment of PIP contractures with Xiapex. This is particularly important for cords situated at the PIP joint of the fifth finger.

Most patients experiencing tendon/ligament rupture or injury have gone on to have successful surgical repair. Early diagnosis and prompt evaluation and treatment are important because tendon rupture/ligament injury may potentially affect overall hand function. Cases of skin laceration requiring skin graft after finger extension procedures have been reported post-marketing. Signs or symptoms that may reflect serious injury to the treated finger/hand after injection or manipulation should be promptly evaluated because surgical intervention may be required. A higher rate for skin laceration has been shown following two concurrent injections in the same hand in a controlled post-marketing trial.

Undesirable effects

Adverse reactions

In the clinical development programme of Xiapex (n=1082), nearly all patients experienced adverse reactions associated with administration of Xiapex and/or to the finger extension procedure to disrupt the cord. The majority of these adverse reactions were local reactions of mild to moderate severity, which resolved within two weeks post-injection.

The most commonly reported adverse events included oedema peripheral (localised to the treated extremity), contusion, injection site pain, pain in the extremity and injection site haemorrhage (manifested as bruising rather than frank bleeding).

Some subjects reported skin lesions (tearing of adherent skin overlying the cord) occurring during the finger extension procedure. Caution should therefore be exercised in patients with Dupuytren's cords that adhere to the skin, as they may be at higher risk of skin lesions as a result of the pharmacological effect of Xiapex and the finger extension procedure on the skin overlying the targeted cord.

The incidence of skin laceration (29.1%) was higher for subjects treated with two concurrent injections of Xiapex in Study AUX-CC-867 compared with subjects treated with up to three single injections in the Phase 3 placebo-controlled pivotal studies in Dupuytren's contracture (CORD I and CORD II, n=249) (skin laceration 8.8%). There were no other clinically relevant differences between two concurrent injections of Xiapex in the same hand and up to three single injections of Xiapex in the types of adverse events reported (ie, most adverse events were local to the treated extremity and of mild or moderate intensity).

Cases of skin laceration requiring skin graft after finger extension procedures have been reported post-marketing. Signs or symptoms that may reflect serious injury to the treated finger/hand after injection or manipulation should be promptly evaluated because surgical intervention may be required.

Table 3 lists adverse reactions that occurred in >5% of the patients in the clinical development programme.

Table 3. Adverse reactions associated with Xiapex[5]

Adverse Reaction	Xiapex (n=1082)
Oedema peripheral	76.7%
Contusion	54.2%
Injection site pain	40.6%
Pain in extremity	35.8%
Injection site haemorrhage	34.0%
Tenderness	28.5%
Injection site swelling	24.5%
Ecchymosis	17.9%
Pruritus	12.5%
Skin laceration	10.9%
Lymphadenopathy	10.9%
Blood blister	9.0%
Axillary pain	6.7%
Injection site pruritus	5.3%
Haematoma	5.2%

As expected when foreign proteins are injected into human tissues, an antibody response is elicited. In the clinical programme, one month after the first injection of Xiapex most of the subjects had antibodies detected against both AUX-I and AUX-II. After a third or fourth injection of Xiapex, all treated subjects were seropositive for both AUX-I and AUX-II antibodies. No apparent correlation of antibody development to clinical response or adverse reaction was observed.

There is a theoretical risk of interference between anti drug antibodies against Xiapex and human matrix metalloproteinases. However, adverse events indicating the development or exacerbation of autoimmune disease or the development of a musculoskeletal syndrome (MSS) have not been observed in the clinical programme. If it were to develop, MSS would occur progressively and is characterised by one or more of the following signs and symptoms: arthralgia, myalgia, joint stiffness, stiffness of the shoulders, hand oedema, palmar fibrosis and thickening or nodules forming in the tendons.

Serious adverse reactions

The majority of serious adverse reactions reported in patients treated with Xiapex were confined to the treated hand. These included six cases of tendon rupture and one case of pulley injury. All these cases occurred with contractures at the level of the PIP joint of the fifth finger. There was also one case of tendonitis reported.

Care should be taken when injecting Xiapex into cords contracting the PIP joints as clinical studies indicate an increased risk of tendon rupture and ligament injury associated with treatment of PIP contractures with Xiapex. This is particularly important for cords situated at the PIP joint of the fifth finger.

In addition, one case each of complex regional pain syndrome and sensory abnormality of the treated hand occurred. These serious adverse reactions were uncommon in the clinical programme, with a frequency of ≥1/1000 and ≤1/100.

In the post-marketing clinical study AUX-CC-867 one case of an anaphylactic reaction was reported in a patient who had previous exposure to Xiapex for the treatment of Dupuytren's contracture.

Further information is available on request by emailing: medical.info@sobi.com

Tel: +44 (0) 1223 891854

Additional copies of the educational materials can be ordered by via: mail.uk@sobi.com

References

1. Rayan G. Hand Clin (1999) 15(1):73–86.
2. Hughes TB. et al. J Am Soc Surg Hand (2003) 3(1):27–40.
3. Townley W et al. BMJ (2006) 332;397–400.
4. McGrouther DA, Hand (1982) 14(3):215–236.
5. Data on File (FDA Submission dossier. Auxilium Pharmaceuticals 2009).
6. Xiapex SPC

Reporting of suspected adverse reactions

Reporting suspected adverse reactions after authorisation of the medicinal product is important. It allows continued monitoring of the benefit/risk balance of the medicinal product. Healthcare professionals are asked to report any suspected adverse reactions via:

United Kingdom
Yellow Card Scheme
Website: www.mhra.gov.uk/yellowcard

Ireland
HPRA Pharmacovigilance
Earlsfort Terrace
IRL - Dublin 2
Tel: +353 1 6764971
Fax: +353 1 6762517
Website: www.hpra.ie
e-mail: medsafety@hpra.ie

Adverse events should be reported. Reporting forms and information in the UK can be found at: www.mhra.gov.uk/yellowcard and in Ireland they can be found at www.hpra.ie

Adverse events should also be reported to Swedish Orphan Biovitrum Ltd by email: drugsafety@sobi.com

Sobi
Swedish Orphan Biovitrum Ltd
Suite 2, Riverside 3, Granta Park, Great Abington,
Cambridgeshire, CB21 6AD, United Kingdom
Tel: +44 (0) 1223 891854 www.sobi-uk.co.uk

Date of preparation: Oct2016 NP-1535